


Section 22

Development of the Palmaz stent

Julio C. Palmaz

Development of the Palmaz stent



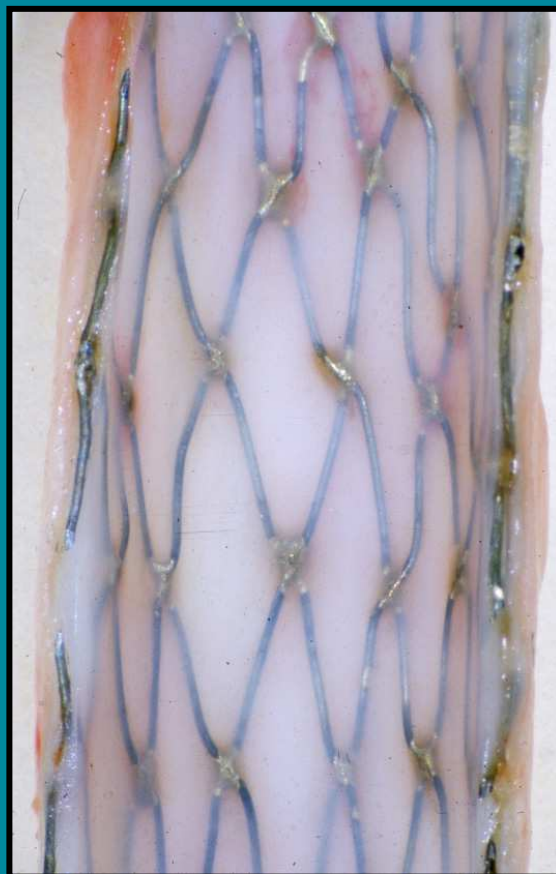
Hand-woven balloon-expandable stent

Development of the Palmaz stent




Fermin O. Tio, pathologist (left) and Julio Palmaz (right)

Development of the Palmaz stent



Three-month specimen of a hand-woven balloon-expandable stent in the canine abdominal aorta

Development of the Palmaz stent




First stents by EDM

Development of the Palmaz stent




Rusty in retirement, as a pet of Julio Palmaz

Development of the Palmaz stent



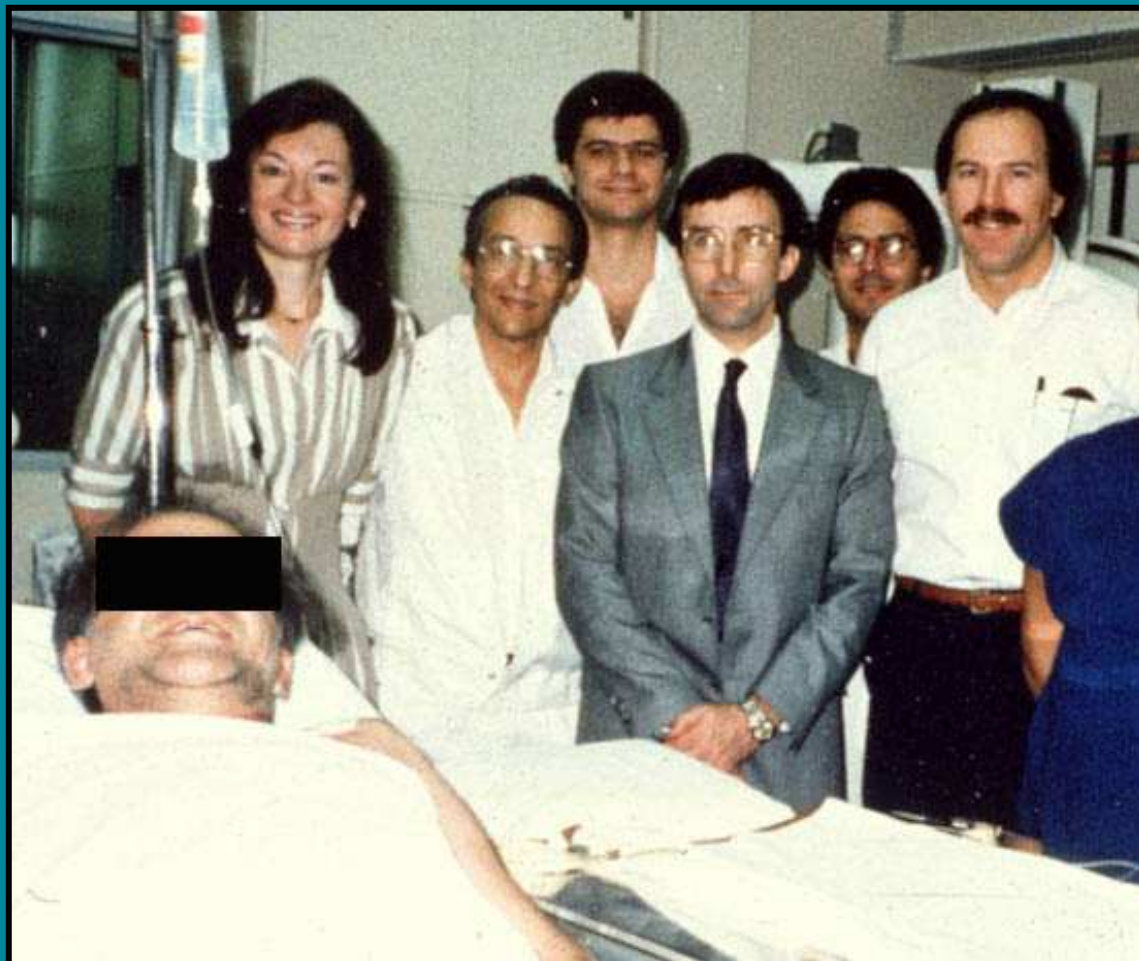Balloon-expandable Palmaz–Schatz stent

Development of the Palmaz stent



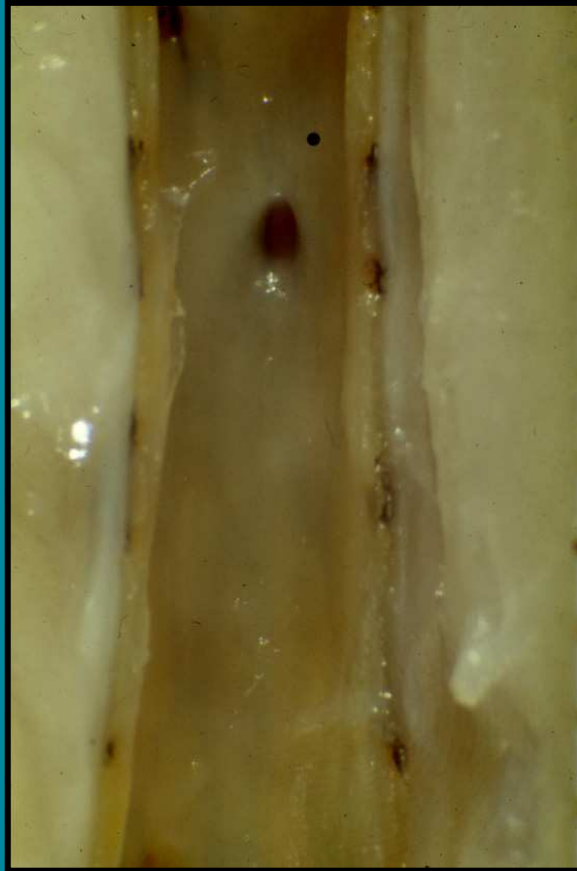
Palmaz–Schatz stent with spiral connectors

Development of the Palmaz stent



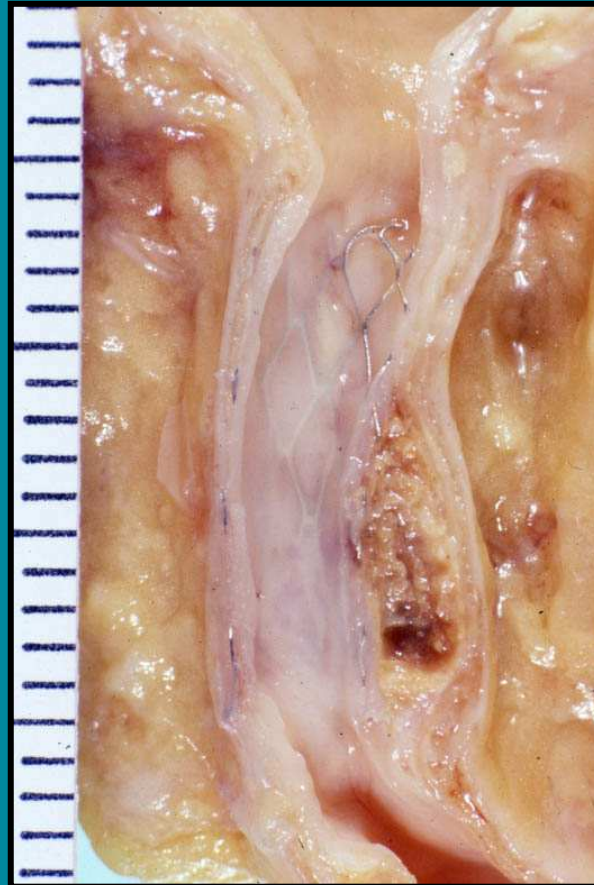A photo with the patient, after the placement of the first coronary stent

Development of the Palmaz stent



Gross specimen of a coronary stent after seven years in a dog's coronary vessel

Development of the Palmaz stent



Gross specimen of a proximal right coronary artery stent, placed 18 months before