


## Section 4

### Left heart catheterization and percutaneous transfemoral coronary angiography

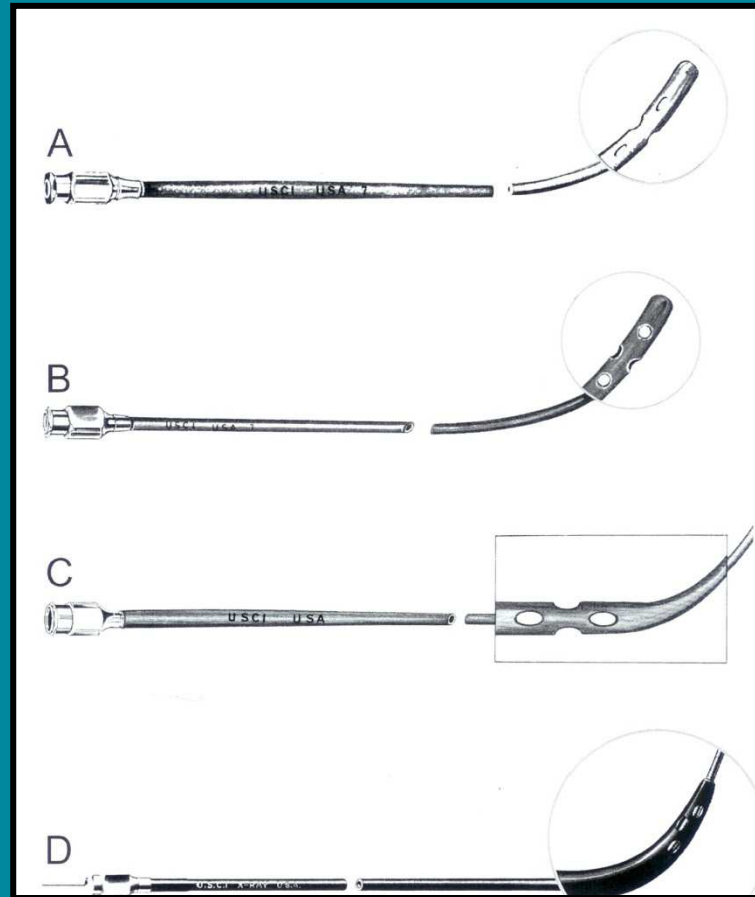
Martial G. Bourassa

## Left heart catheterization and percutaneous transfemoral coronary angiography




Sven-Ivar Seldinger

## Left heart catheterization and percutaneous transfemoral coronary angiography




Modifications to the initial Cournand catheter

## Left heart catheterization and percutaneous transfemoral coronary angiography




Seldinger needle

## Left heart catheterization and percutaneous transfemoral coronary angiography



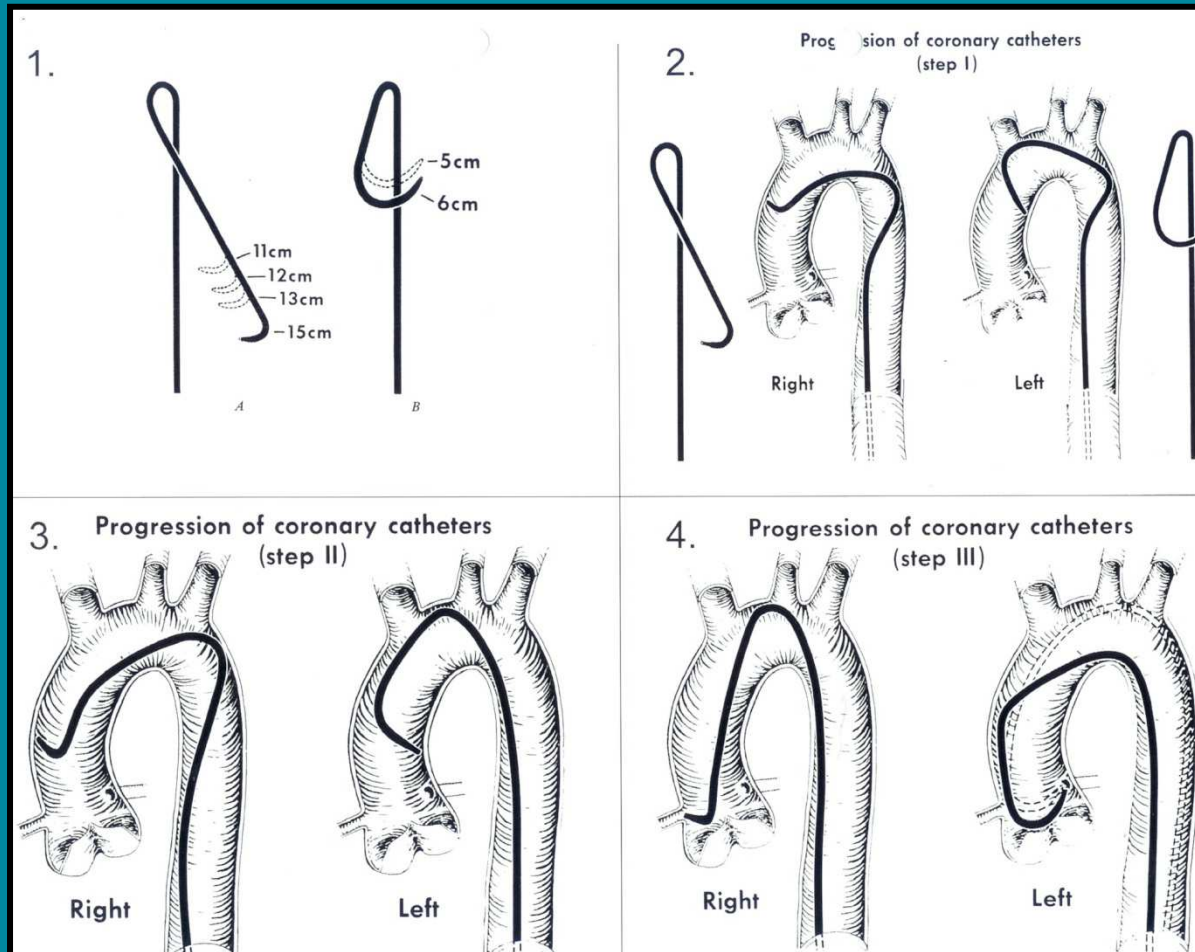
Teflon-coated spring coil guide wires

## Left heart catheterization and percutaneous transfemoral coronary angiography



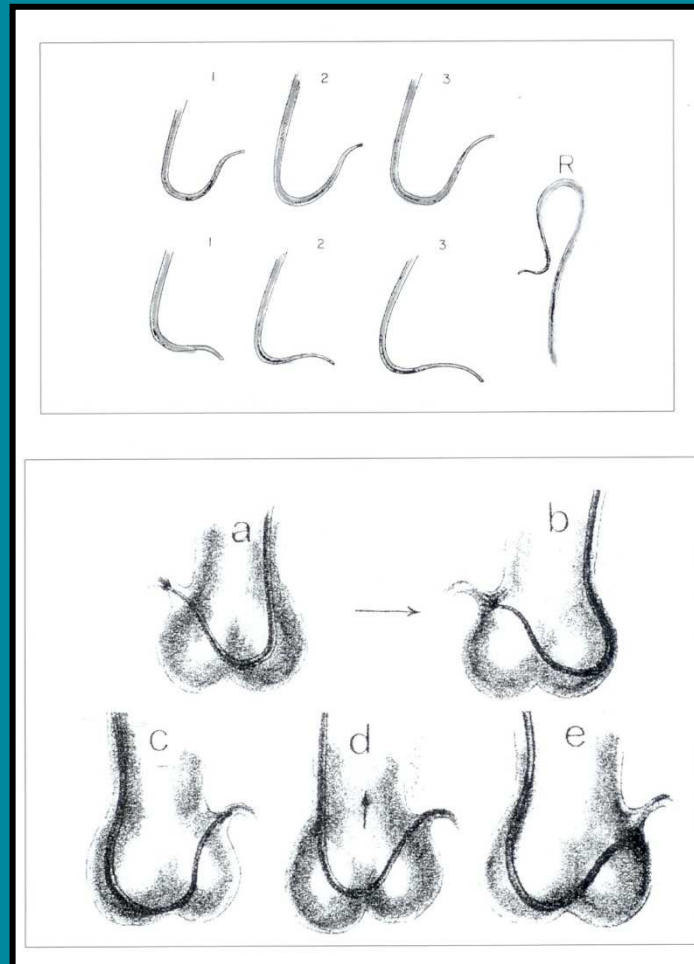
Pigtail catheter

# Left heart catheterization and percutaneous transfemoral coronary angiography



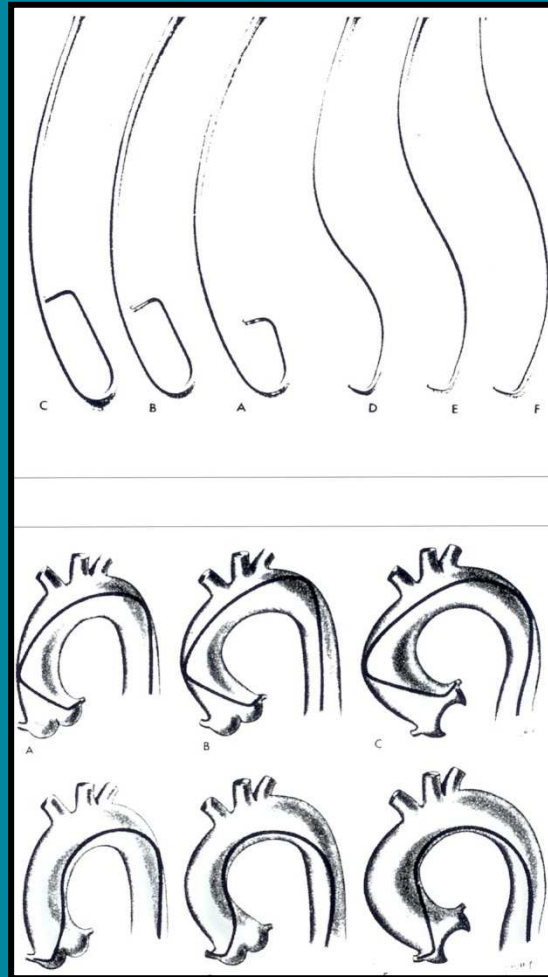
Preformed coronary catheters: design, shapes and techniques

## Left heart catheterization and percutaneous transfemoral coronary angiography



Preformed coronary catheters: design, shapes and techniques

## Left heart catheterization and percutaneous transfemoral coronary angiography



Preformed coronary catheters: design, shapes and techniques